

Oligodendrogliomas: Molecular Biology and Treatment

JACOLIEN E. C. BROMBERG, MARTIN J. VAN DEN BENT

Neuro-Oncology Unit, Daniel den Hoed Cancer Center/Erasmus University Medical Center, Rotterdam, The Netherlands

Key Words. Oligodendroglioma • Oligoastrocytoma • 1p • 19q • *MGMT* • Temozolomide

Disclosures

Jacolien E. C. Bromberg: None; **Martin J. van den Bent:** *Consultant/advisory role:* Schering Plough; *Honoraria:* Schering Plough.

Section editors **Jean-Yves Delattre** and **Tracy Batchelor** have disclosed no financial relationships relevant to the content of this article.

The content of this article has been reviewed by independent peer reviewers to ensure that it is balanced, objective, and free from commercial bias.

Target audience: Physicians who wish to advance their current knowledge of clinical cancer medicine in neuro-oncology.

LEARNING OBJECTIVES

1. Evaluate the current challenges in the histological diagnosis of oligodendroglial tumors and apply best practices to optimize patient outcomes.
2. Analyze the molecular alterations in different subsets of tumors with oligodendroglial morphology.
3. Formulate treatment options for your patients with newly diagnosed and recurrent oligodendroglial tumors.

CME

This article is available for continuing medical education credit at CME.TheOncologist.com.

ABSTRACT

Oligodendroglial tumors continue to receive much attention because of their relative sensitivity to chemotherapy. The histological diagnosis of oligodendroglial tumors is subject to considerable interobserver variation. The revised 2007 World Health Organization classification of brain tumors no longer accepts the diagnosis “mixed anaplastic oligoastrocytoma” if necrosis is present; these tumors should be considered glioblastomas (perhaps with oligodendroglial features). The 1p/19q codeletion that is associated with sensitivity to chemotherapy is mediated by an unbal-

anced translocation of 19p to 1q. Randomized studies have shown that patients with 1p/19q codeleted tumors also have a better outcome with radiotherapy. Histologically more atypical tumors are less likely to have this 1p/19q codeletion; here, other alterations usually associated with astrocytic tumors are often found. Some patients with tumors with classic histological features but no 1p/19q codeletion still have a very favorable prognosis.

Currently, the best approach for newly diagnosed anaplastic oligodendroglial tumors is unclear. Early ad-

Correspondence: Martin J. van den Bent, M.D., Neuro-Oncology Unit, Daniel den Hoed Cancer Center/Erasmus University Medical Center, PO Box 5201, 3008AE Rotterdam, The Netherlands. Telephone: 31-10-4391415; Fax: 31-10-4391031; e-mail: m.vandenbent@erasmusmc.nl Received November 14, 2008; accepted for publication January 12, 2009; first published online in *The Oncologist Express* on January 31, 2009. ©AlphaMed Press 1083-7159/2009/\$30.00/0 doi: 10.1634/theoncologist.2008-0248

juvant chemotherapy does not provide a better outcome than chemotherapy at the time of progression. The value of combined chemoradiation with temozolomide has not been proven in these tumors, and could at least theoretically be associated with greater neurotoxicity. Tumors with 1p and 19q loss can also be managed with early chemotherapy, while deferring radiotherapy to

the time of further progression. The presently available second-line chemotherapy results are modest, and better salvage treatments are necessary. The molecular explanation for the greater sensitivity of 1p/19q codeleted tumors is still unclear, and this could, in part, be explained by more frequent *MGMT* promoter gene methylation. *The Oncologist* 2009;14:155–163

INTRODUCTION

Oligodendroglioma (OD) and mixed oligoastrocytoma (OA) constitute 5%–20% of all glial tumors. They are predominantly tumors of adulthood, with a peak incidence between the fourth and sixth decade of life; low-grade ODs tend to arise in slightly younger patients. Until some 15 years ago, the diagnosis of OD was merely a pathological entity, which changed with the recognition of the marked sensitivity to procarbazine, lomustine, and vincristine (PCV) chemotherapy of these tumors [1, 2]. A second development was the identification of the combined loss of the short arm of chromosome 1 (1p) and the long arm of chromosome 19 (19q) as the typical genetic lesions of OD, occurring in 60%–90% of ODs [3–6]. This was followed by the recognition that these 1p/19q codeleted tumors, in particular, have an excellent response to chemotherapy [4, 7–9]. Patients with ODs with the combined loss of 1p and 19q not only have a better response to chemotherapy, they also have a more indolent clinical course and a longer lasting response to radiotherapy (RT). These observations have led to the current tendency to consider 1p and 19q loss low-grade OD and anaplastic oligodendroglioma (AOD) as a separate biological entity, at least within clinical trials [8, 10]. New data at least question this assumption.

HISTOLOGY

The current World Health Organization (WHO) definition of OD is “a well-differentiated, diffusely infiltrating tumor of adults, typically located in the cerebral hemispheres and composed predominantly of cells morphologically resembling oligodendroglia” [11]. By definition, mixed OA tumors have morphologic characteristics of both astrocytic tumors and pure ODs. Recent European Organization for Research and Treatment of Cancer (EORTC) and Radiation Therapy Oncology Group (RTOG) trials used the presence of 25% oligodendroglial elements as the arbitrary cutoff point for the diagnosis of a mixed tumor. Since the results of one study that noted that the outcome of patients with mixed anaplastic oligoastrocytoma (AOA) with necrosis was similar to that of glioblastoma patients were available, the recent 2007 WHO classification of brain tumors no longer

accepts the diagnosis of mixed OA if necrosis is present [6, 12]. These tumors are now considered amongst the glioblastomas, perhaps with the addition of “with oligodendroglial features.” Whether or not there is any clinical significance, however, to identifying such oligodendroglial components in glioblastomas is unclear. Previous studies have shown that these tumors do indeed have a molecular pattern comparable with that of glioblastoma, with epidermal growth factor receptor gene (*EGFR*) amplification, phosphatase and tensin homologue deleted on chromosome 10 gene (*PTEN*) mutations, and loss of chromosome 10, but rarely combined 1p and 19q loss [13–15]. Of note, however, another large study did report somewhat better survival in patients with so-called grade 4 OAs (the diagnosis of which required necrosis) than in glioblastoma patients [16]. The median survival time in the AOA grade 4 group was 15.6 months, compared with 10.9 months in the glioblastoma group.

In pure AOD, the impact of necrosis is unclear. Miller et al. [6] did not find any impact of necrosis in pure AOD, nor did a review analysis of the North American prospective randomized study on oligodendroglial tumors [17]. In contrast, a similar European study found that both endothelial proliferation and necrosis were related to survival in AOD patients [18]. These subtle differences may be related to differences in the rather subjective histological criteria. From all studies, it is clear though that the outcome of AOD patients, even with necrosis, remains distinctly better than that of glioblastoma patients, which is not the case for mixed AOAs with necrosis.

RELIABILITY OF THE HISTOLOGICAL DIAGNOSIS

Several studies have shown that considerable interobserver variation is present in the diagnosis of grade III tumors, including oligodendroglial tumors. In one project, 114 samples from a large prospective European trial were reviewed by nine independent pathologists [19]. The panel reached consensus (six or more of the nine agreeing on the diagnosis) on the diagnosis of AOD in 52% of the tumors that had been diagnosed as AOD by the local pathologists, whereas only 8% of the local diagnoses of AOA were confirmed

with consensus. The κ coefficients of the individual panelists for the 52 cases with a consensus diagnosis of AOD were in the range of 0.46–0.72. A similar study on the North American randomized study investigated the interobserver variation in the diagnosis of “classical for oligodendroglioma” (CFO) (loosely defined as round regular nuclei, monomorphic appearance, perinuclear haloes, etc.) among experienced neuropathologists (Fig. 1) [17]. Tumor specimens from 247 patients were available for this review. Although the authors considered the outcome of the study supportive of an approach to clinical trials on OD, in which patients can only be included after central review, the interobserver agreement was only modest ($\kappa = 0.55$), and one reviewer did not identify 22% of the CFO cases identified by consensus. In the above-mentioned study on CFO, which used five independent reviewers, a consensus diagnosis (four of five neuropathologists agreeing) was obtained in 83% of cases. In another series, a rather high degree of agreement was reported [20]. Most likely, close interaction among pathologists leads to a better diagnostic agreement, although that holds an element of subjectivity (e.g., within that specific group).

GENETICS: 1p/19Q CODELETION AND TRANSLOCATION

It was recently demonstrated that the combined loss of 1p and 19q is mediated by an unbalanced translocation of 19p to 1q [21, 22]. Most likely, a centrosomal or pericentrosomal translocation of chromosomes 1 and 19 results in two derivative chromosomes, der(1,19)(p10;q10) and der(1,19)(q10;p10), after which the derivative chromosome with the short arm of chromosome 1 and the long arm of chromosome 19 is lost. A possible explanation for this translocation is the strong homology of the centromeric regions of chromosomes 1 and 19. For the analysis of 1p loss in OD, it is important that the loss of the entire short arm of chromosome 1 is assessed. Partial 1p deletions do occur in glioblastoma, are not associated with 19q loss, and carry a poor prognostic significance [23]. Because fluorescence in situ hybridization probes used to assess 1p loss are often located on 1p36.6, one needs to be aware that this will also pick up loss of the tip of 1p. In tumors in which codeletion of 1p and 19q is present, the codeletion is generally distributed throughout the tumor, even in areas with more astrocytic morphology [24]. Furthermore, the loss of 1p and 19q is retained at the time of progression, regardless of morphological changes, suggesting that 1p/19q loss is an early genetic event [15, 25].

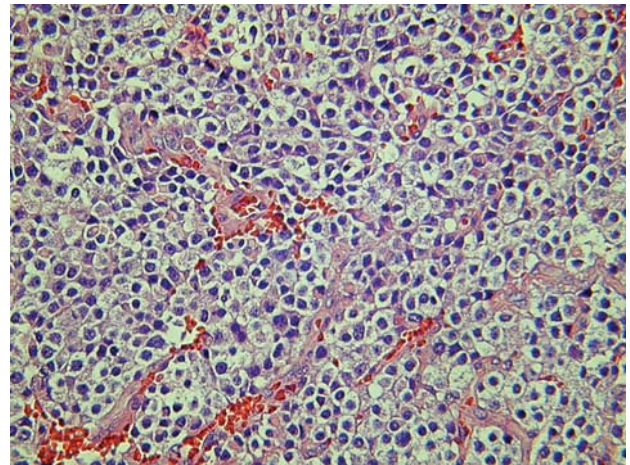


Figure 1. Classic oligodendroglioma, with fried egg appearance (which actually is an artificial fixation artifact).

HISTOMORPHOLOGY AND 1p/19Q CODELETION

A clear association exists between codeletion of 1p and 19q and a classic histological appearance (perinuclear halo, chicken-wire vascular pattern) [8, 17, 26]. The 1p/19q codeletion is present in 61%–89% of AOD cases, but in only 13%–20% of patients with AOA [6, 27]. Of note, McDonald et al. [27] confirmed the close association between CFO and 1p/19q codeletion, with a higher likelihood of 1p and 19q loss if more pathologists judged the tumor to be CFO. In mixed OAs with predominant oligodendroglioma morphology, the percentage of tumors showing 1p and 19q loss drops to 39%, emphasizing that even the presence of minor astrocytic elements significantly reduces the chance of finding 1p and 19q loss [15].

Still, some atypical ODs have 1p/19q codeletions and some typical ODs do not show 1p and 19q loss. However, the outcome of patients with non-1p/19q codeleted tumors but with typical histological appearance was reported to be equally favorable in a large prospective U.S. trial [17]. Another study reported loss of 1p and 19q to be related, in particular, to outcome in patients with tumors with classic histologic features [27].

OTHER GENETIC ABERRATIONS

Compared with low-grade ODs, AODs usually have additional chromosomal deletions, in particular loss of heterozygosity for 9p and/or deletion of the *CDKN2A* gene (p16) [15]. These occur in 33%–50% of AODs and are associated with tumor progression. As a rule, other chromosomal abnormalities are found in low-grade and in high-grade ODs with atypical morphological features. These are typically associated with astrocytomas and are usually mutually exclusive with 1p/19q codeletion (e.g., *TP53* mutations in low-grade tumors and *EGFR* amplification, 10q

loss, and *PTEN* mutations in anaplastic tumors) [15, 28–31]. Deletions on chromosome 10 have been reported in 19%–25% of anaplastic oligodendroglial tumors (AOTs) [15, 32]. Amplification of the *EGFR* gene on chromosome 7p occurs in 20%–30% of AOTs, but reportedly never in those with deletion of 1p and 19q, and correlates with a poor prognosis [14, 15, 33, 34]. Similarly, molecular analysis of the prospective EORTC study on AOTs observed more frequent loss of chromosome 10 and amplification of the *EGFR* gene in tumors diagnosed as mixed OAs with necrosis [18]. Again, these aberrations were inversely correlated with the 1p/19q codeletion. This suggests that these tumors are derived from different precursor cells. This hypothesis is supported by the marked differences in outcome and prognosis, with a superior outcome in the presence of 1p and 19q loss, and with poor survival in AODs with the loss of 10q and/or the amplification of *EGFR* [30]. The presence of 10q loss or *EGFR* amplification in pure AODs is sufficiently rare to suggest an alternate diagnosis (e.g., small cell glioblastoma) [15]. AOAs do not appear to constitute a fixed class of tumors, but rather a morphological continuum between pure ODs and astrocytomas. Only in exceptional cases do mixed tumors show genetically distinct clones of tumor within histologically different areas [35].

In an intriguing study on 70 patients with grade II and III oligodendroglial tumors, a number of prognostically unfavorable genomic alterations were identified, in particular, gain of 7p and 8q and loss of 9p, 10q, and 18q [36]. In the anaplastic tumors, the presence of the 1p/19q codeletion was a favorable prognostic factor, particularly if no other unfavorable genomic aberrations had been identified. Similarly, outcome was equally favorable in patients without 1p/19q codeletion and also without other unfavorable genomic aberrations. However, if 1p and 19q loss was accompanied by unfavorable alterations, the prognosis was poor. Others have reported that the prognostic impact of 1p and 19q loss is mainly present in tumors with classic AOD morphology, but not in oligodendroglial tumors with atypical features or in mixed AOAs [6, 27].

METHYL GUANINE METHYLTRANSFERASE GENE (*MGMT*) AND ALKYLTRANSFERASE

No clear explanation is yet available for the favorable response to chemotherapy of AOTs as compared with astrocytic tumors. Previous studies suggested that the nuclear enzyme alkyltransferase, also known as methyl guanine methyltransferase (*MGMT*), which mediates at least part of the cell resistance to alkylating and methylating agents, is less expressed in ODs and perhaps even more so in 1p/19q codeleted tumors [37]. *MGMT* expression can be silenced by *MGMT* promoter gene methylation, which was initially

reported to occur in 47% of low-grade ODs without a correlation with 1p/19q codeletion [38]. Other studies did, however, find a correlation between 1p/19q codeletion and *MGMT* promoter methylation, which was observed in up to 80%–90% of 1p/19q codeleted tumors [39–41]. *MGMT* promoter gene methylation occurs in up to 40%–50% of glioblastomas; it is therefore unlikely that this event alone accounts for the entire difference in sensitivity to chemotherapy between astrocytic tumors and oligodendroglial tumors, or for the greater chemosensitivity in 1p/19q codeleted tumors.

WHY ARE 1P/19Q CODELETED TUMORS MORE SENSITIVE TO TREATMENT?

Why 1p/19q codeleted tumors are more sensitive to RT and chemotherapy remains an unanswered question. There are a number of possible explanations: loss of genes that mediate resistance to treatment, the assumption that 1p and 19q loss is an epiphenomenon that identifies a tumor that is more sensitive to treatment (e.g., with less frequent other unfavorable mutations/alterations), or an association between 1p and 19q loss and other genetic events (e.g., *MGMT* promoter gene methylation). It is clear that ODs with 1p and 19q loss have gene expression profiles that differ from those of other gliomas [42]. The gene expression profile of 1p/19q codeleted ODs partially resembles that of the normal brain (proneural expression pattern) [43].

Several studies have shown that other specific epigenetic aberrations are observed in 1p/19q codeleted tumors. The maternally imprinted *DIRAS3* tumor suppressor gene is located on 1p31, the expression of which is significantly decreased because of methylation in ODs with 1p loss [44]. Biallelic *DIRAS3* inactivation has been associated with survival. Similarly, the expression of the *CITED4* gene on 1p34.2 seems decreased through hypermethylation [45]. Again, *CITED4* hypermethylation has been associated with longer survival. *EMP3*, located at 19q13.3, is another example of a gene that is frequently hypermethylated in OD and astrocytoma, but not in primary glioblastoma [46]. In all these cases, one allele is silenced because of loss and the other through hypermethylation. These findings support a major role for epigenetic phenomena in the pathogenesis of OD.

IS 1P/19Q CODELETION PREDICTIVE OF OUTCOME TO CHEMOTHERAPY, OR PROGNOSTIC?

Initial studies observed that response and survival rates were better in patients with OD with combined 1p and 19q loss than in those without 1p and 19q loss. Several studies have found the presence or absence of combined loss of 1p

Table 1. Median survival time and 5-year overall survival rate according to combined 1p and 19q loss status in the EORTC 26951 and RTOG 9402 trials on (neo-)adjuvant PCV chemotherapy in anaplastic oligodendroglial tumors [47, 48]

Chromosomal loss	Overall survival			
	Median, mos (95% CI)		5-Year, % (95% CI)	
	RT/PCV	RT	RT/PCV	RT
Combined 1p and 19q loss				
EORTC	NR	NR	74 (57–85)	75 (55–87)
RTOG	NR	NR (3.4–NR)	72 (54–83)	66 (50–78)
No combined 1p and 19q loss				
EORTC	25.2 (18.9–42.6)	21.4 (17.6–30.0)	34 (24–43)	28 (19–36)
RTOG	2.7 (2.0–5.5)	2.8 (1.9–4.4)	37 (24–50)	31 (19–45)

Abbreviations: CI, confidence interval; EORTC, European Organization for Research and Treatment of Cancer; NA, not available; NR, not reported; PCV, procarbazine, lomustine, and vincristine; RT, radiotherapy; RTOG, Radiation Therapy Oncology Group.

and 19q to be the most important prognostic factor for overall survival in AOTs [5, 47, 48]. The median survival duration was >6–7 years in the presence of the 1p/19q codeletion, and 2–3 years in the absence of the codeletion. For low-grade OD or OA, median survival time were 12–15 years for 1p/19q codeleted patients and 5–8 years for patients without the deletion [15, 21]. In all these studies, patients were treated with either chemotherapy or RT, and the longer progression-free survival time in RT-only treated patients suggests that the 1p/19q codeletion is more a prognostic than a predictive factor [26, 48]. This view was corroborated by studies that suggested that ODs have a more indolent behavior, even prior to the initiation of treatment [8, 10]. Indeed, a study measuring growth speed in low-grade gliomas observed a slower growth rate in 1p/19q codeleted ODs [49]. However, in a recent study of untreated low-grade ODs and AOTs, on multivariate analysis, the presence of 1p and 19q loss was found not to be prognostic for progression-free survival [20]. The overall picture that emerges from this is that 1p/19q codeleted tumors tend to have slower growth rates and to be more responsive to treatment than tumors without this codeletion. In that sense, the 1p/19q codeletion identifies a favorable prognostic subgroup, although it also predicts outcome to treatment. However, it may not really help in deciding on chemotherapy or not, because RT is also likely to give good treatment results.

TREATMENT OF LOW-GRADE TUMORS

Following the favorable response of AOTs to chemotherapy, chemotherapy as initial treatment, employing either PCV or temozolomide, for patients with progressive low-grade ODs has been investigated in a limited number of retrospective or phase II studies. Radiological response rates,

including the category minor response, of 30%–70% have been reported with PCV or with temozolomide, with a median time to progression of 2–3 years [49–52]. Response may be delayed—one series described a median time to maximum response of 12 months—and clinical response (e.g., better seizure control) is frequently more impressive than radiological response. Response rates are higher and time to progression is longer in 1p/19q codeleted tumors. Whether first-line chemotherapy for low-grade OD is superior to RT is unknown; the results of a current EORTC phase III study on this subject are awaited. In the meantime, for patients requiring large RT portals for large tumors, upfront treatment with PCV or temozolomide to avoid or delay the risk for late cognitive defects is a reasonable treatment option.

TREATMENT OF ANAPLASTIC TUMORS

Newly Diagnosed AOD and AOA: (Neo-)adjuvant Chemotherapy Trials

Two prospective, randomized, controlled trials in AOTs have shown that (neo)adjuvant PCV chemotherapy given in addition to 60 Gy of RT does not result in a longer overall survival time, although it does lead to a longer progression-free survival time. The first of these trials, RTOG 94–02, randomized patients to either four cycles of upfront intensified PCV chemotherapy followed by RT to a dose of 60 Gy or RT only [47]. The second trial (EORTC 26951) randomized patients to 60 Gy of RT followed by six cycles adjuvant PCV or to 60 Gy of RT only [48]. Table 1 summarizes the progression-free survival and overall survival results of these studies. In both trials, the majority of patients randomized to the RT arm received PCV at progression, which most likely explains the longer progres-

sion-free survival time without a longer overall survival time. Because of this, these trials in fact investigated early (adjuvant) versus delayed (at the time of progression) PCV chemotherapy. Even in the 1p/19q loss subgroup analysis, no overall survival benefit of early (i.e., adjuvant or neoadjuvant) PCV could be demonstrated (Table 1). The conclusion of both trials is that in AOD, early PCV given sequentially with RT does not provide a superior outcome to initial RT only followed by chemotherapy at the time of recurrence.

In a rather complex recent German study, patients with grade III tumors (anaplastic astrocytoma, AOA, AOD) were randomized to either RT or chemotherapy; within the chemotherapy arm, patients were further randomized between PCV and temozolomide [53]. The trial design included crossover to the other treatment (chemotherapy or RT) at the time of progression. Neither the initial randomization (RT or chemotherapy) nor the type of chemotherapy regimen impacted survival. In the first analysis of the study, MGMT methylation status appeared to be a more important prognostic factor than 1p/19q status.

Chemoirradiation with Temozolomide?

The current clinical question is whether combined chemoirradiation with temozolomide should also be used for AOTs. The negative outcome of the adjuvant PCV trials is in contrast to the observed survival benefit in glioblastoma patients of combined chemoirradiation with temozolomide, especially in tumors with a methylated MGMT promoter gene [54, 55]. A particular consideration here is that patients with anaplastic tumors with combined 1p and 19q loss have a median survival duration >6–7 years. Hence, the late neurotoxicity of a combined radiochemotherapy approach is potentially an issue. This is clearly less so for tumors without 1p and 19q loss, but here the benefit of the combined regimen is also unproven. Current studies are investigating the role of combined chemoirradiation in AODs, including other grade III tumors, with separate trials for tumors with and without combined 1p and 19q loss.

Upfront Chemotherapy in Newly Diagnosed AOT

The chemosensitivity of OTs has made upfront chemotherapy strategies (with or without subsequent RT) increasingly popular. The major rationale for upfront chemotherapy is the wish to defer RT. A few medium-sized and uncontrolled studies are available, in particular, employing temozolomide. One showed, in a young population (median age, 42 years) with 81% of patients having a Karnofsky Performance Status score of 90/100, a median progression-free survival time of 27 months with a 1-week-on/1-week-off dose-dense temozolomide regimen [56]. A small trial on

upfront temozolomide chemotherapy showed a very short time to progression (8 months) in patients without 1p loss, in contrast to all seven patients with 1p loss who were still free from progression at 24 months [57]. In a prospective phase II study carried out by the RTOG, 39 eligible patients were neoadjuvantly treated with 6 months of 1-week-on/1-week-off 150 mg/m² temozolomide, followed by concurrent chemoirradiation with temozolomide [58]. In 32% of patients, an objective response was observed; 10% of patients progressed during neoadjuvant temozolomide. In 28 patients, the 1p/19q status could be assessed; all 17 patients with the 1p/19q codeletion were free from progression at 6 months. No less than 16 of the 20 patients tested had MGMT promoter methylation, all were free from progression at 6 months. Thirteen of the 16 patients with MGMT promoter methylation also had 1p/19q codeletion. The overall survival rate at 30 months was 81%; the 1p/19q codeletion was related to survival. The obvious difficulty in the interpretation of this trial is the short follow-up and absence of control patients, limiting conclusions beyond the well-established superior outcome for patients with 1p/19q codeleted AOTs with upfront temozolomide.

In a phase II trial in 69 patients with newly diagnosed anaplastic or aggressive OD, the intensive PCV regimen was followed by high-dose thiotepa with autologous stem cell rescue, without RT. The median progression-free survival time in the 39 patients who received the autologous stem cell procedure was 78 months, and the median overall survival time had not been reached. Eighteen patients (46%) had relapsed [59]. In view of the patient selection and the absence of a control arm, final conclusions on the meaning of these results are impossible to draw; many patients with AOTs have similar survival times without such intensive treatments. The trial showed, though, that a longer progression-free survival time without initial RT is possible. The German NOA4 trial showed that patients treated with chemotherapy first had a similar survival benefit to patients managed with RT first [53]. That trial, which basically studied sequential treatment (RT first or chemotherapy first), demonstrated that whatever sequence is followed, the results are comparable. The choice for chemotherapy or RT may well come down to deciding between side effects: local side effects of a short series of RT or systemic side effects of (expensive) chemotherapy of 1-year duration.

Second-Line Chemotherapy in Recurrent AOTs

Second-line PCV after failure with temozolomide induced a response in only 17% of patients, but 50% were still free from progression at 6 months and 21% were still free from progression at 12 months [60]. Similarly, 25% of patients

had an objective response to temozolomide after PCV and 29% and 11% of patients were free from progression after 6 and 12 months, respectively [61]. Occasionally, patients that do not respond to one regimen are responsive to the other. However, in general, response rates to second-line chemotherapy are modest, even in 1p/19q codeleted tumors (and regardless of the sequence chosen—temozolomide first or PCV first). Still, very few other agents have been systematically evaluated in AOTs. One trial found PCV chemotherapy followed by an autologous bone marrow transplantation after a myeloablative procedure with melphalan to be too toxic, without clearly producing superior results [62]. Response to carboplatin monotherapy was similar to that of temozolomide, with 13% of patients responding and with 35% and 9% 6- and 12-month progression-free survival times, respectively [63]. These results were obtained, however, at the cost of considerable myelotoxicity. In a study of CPT-11 on 22 patients with 1p/19q codeleted AODs, the response rate was 23% and the 6- and 12-month progression-free survival times were 33% and 4.5%, respectively [64]. Despite the upregulation of platelet-derived growth factor (PDGF) signaling pathways in most ODs, the PDGF receptor tyrosine kinase inhibitor imatinib did not show any activity in recurrent OD or AOD/AOA [65]. Clearly, for a further improvement in outcome after failing first-line chemotherapy and RT, other approaches need to be developed.

CONCLUSIONS

The histological diagnosis of OD is still hampered by significant interobserver variation. The clear correlation between classic histology and 1p/19q codeletion has led some to use this codeletion as a marker for OD, and it has even been suggested to build this into the diagnosis. However, it is becoming increasingly questionable whether this nice and simple conclusion is justified. Several studies have now

observed that patients with tumors with classic oligodendroglial morphology, even without 1p/19q codeletions, have a better prognosis than those with astrocytic tumors [17, 36, 53]. This argues in favor of the use of more strict morphological criteria for oligodendroglial tumors, although even in the hands of experts up to 20% of CFO cases may not be agreed upon [17]. The recently modified WHO classification considers necrosis to no longer be compatible with the diagnosis of mixed AOA, which should thus be considered glioblastoma (with some oligodendroglial features).

The basic molecular characteristic of 1p/19q codeletion and the explanation for the sensitivity of these tumors to RT and chemotherapy is still unresolved. It is also unclear whether that sensitivity is to be expected in tumors with classic morphology in the absence of the 1p/19q codeletion. Despite the recent data suggesting a favorable subset of these tumors, the initial studies suggested that 1p/19q status was better correlated with response to chemotherapy than with morphology [7, 8].

For today's patients, sequential treatment with RT and chemotherapy, depending on the expected side effects and treatment efficacy, seems to be the optimal approach, with currently no solid data available to help in making the choice between initial RT and initial chemotherapy [53]. The value of concurrent chemoradiation with temozolomide in these tumors has not been established, nor has it been established whether or not this treatment will induce long-term side effects in patients with an expected long survival time.

AUTHOR CONTRIBUTIONS

Conception/design: Martin J. van den Bent, Jacolien E.C. Bromberg
Provision of study materials: Martin J. van den Bent, Jacolien E.C. Bromberg
Collection/assembly of data: Martin J. van den Bent, Jacolien E.C. Bromberg
Manuscript writing: Martin J. van den Bent, Jacolien E.C. Bromberg
Final approval of manuscript: Martin J. van den Bent, Jacolien E.C. Bromberg

REFERENCES

- Cairncross G, Macdonald D, Ludwin S et al. Chemotherapy for anaplastic oligodendroglioma. National Cancer Institute of Canada Clinical Trials Group. *J Clin Oncol* 1994;12:2013–2021.
- van den Bent MJ, Kros JM, Heimans JJ et al. Response rate and prognostic factors of recurrent oligodendroglioma treated with procarbazine, CCNU, and vincristine chemotherapy. Dutch Neuro-oncology Group. *Neurology* 1998;51:1140–1145.
- Reifenberger J, Reifenberger G, Liu L et al. Molecular genetic analysis of oligodendroglial tumors shows preferential allelic deletions on 19q and 1p. *Am J Pathol* 1994;145:1175–1190.
- Smith JS, Alderete B, Minn Y et al. Localization of common deletion regions on 1p and 19q in human gliomas and their association with histological subtype. *Oncogene* 1999;18:4144–4152.
- Smith JS, Perry A, Borell TJ et al. Alterations of chromosome arms 1p and 19q as predictors of survival in oligodendrogliomas, astrocytoma, and mixed oligoastrocytomas. *J Clin Oncol* 2000;18:636–645.
- Miller CR, Dunham CP, Scheithauer BW et al. Significance of necrosis in grading of oligodendroglial neoplasms: A clinicopathologic and genetic study of newly diagnosed high-grade gliomas. *J Clin Oncol* 2006;24:5419–5426.
- Cairncross JG, Ueki K, Zlatescu MC et al. Specific genetic predictors of chemotherapeutic response and survival in patients with anaplastic oligodendrogliomas. *J Natl Canc Inst* 1998;90:1473–1479.
- van den Bent MJ, Looijenga LHJ, Langenberg K et al. Chromosomal anomalies in oligodendroglial tumors are correlated with clinical features. *Cancer* 2003;97:1276–1284.
- Ino Y, Betensky RA, Zlatescu MC et al. Molecular subtypes of anaplastic

- oligodendroglioma: Implications for patient management at diagnosis. *Clin Cancer Res* 2001;7:839–845.
- 10 Walker C, du Plessis DG, Joyce KA et al. Molecular pathology and clinical characteristics of oligodendroglial neoplasms. *Ann Neurol* 2005;57:855–865.
 - 11 Reifenberger G, Kros JM, Burger P et al. Oligodendroglioma. In: Kleihues P, Cavenee WK, eds. *World Health Organization Classification of Tumours. Pathology and Genetics of Tumours of the Nervous System*. Lyon, France: IARC Press, 2000:55–70.
 - 12 Louis DN, Ohgaki H, Wiestler OD et al. WHO classification of tumours of the central nervous system. *Acta Neuropathol* 2007;114:97–109.
 - 13 Jeuken JWM, Nelen MR, Vermeer H et al. *PTEN* mutation analysis in two genetic subtypes of high-grade oligodendroglial tumors: *PTEN* is only occasionally mutated in one of the two genetic subtypes. *Cancer Genet Cytogenet* 2000;119:42–47.
 - 14 Dehais C, Laigle-Donadey F, Marie Y et al. Prognostic stratification of patients with anaplastic gliomas according to genetic profile. *Cancer* 2006;107:1891–1897.
 - 15 Fallon KB, Palmer CA, Roth KA et al. Prognostic value of 1p, 19q, 9p, 10q, and EGFR-FISH analysis in recurrent oligodendroglioma. *J Neuropathol Exp Neurol* 2004;63:314–322.
 - 16 Buckner JC, O'Fallon JR, Dinapoli RP et al. Prognosis in patients with anaplastic oligoastrocytoma is associated with histologic grade. *J Neurooncol* 2007;84:279–286.
 - 17 Giannini C, Burger PC, Berkey BA et al. Anaplastic oligodendroglial tumors: Refining the correlation among histopathology, 1p 19q deletion and clinical outcome in Intergroup Radiation Therapy Oncology Group Trial 9402. *Brain Pathol* 2008;18:360–369.
 - 18 Kouwenhoven MCM, Gorlia T, Kros JM et al. Molecular analysis of anaplastic oligodendroglial tumors in a prospective randomized study: A report from EORTC study 26951. *Neuro Oncol*, in press.
 - 19 Kros JM, Gorlia T, Kouwenhoven MC et al. Panel review of anaplastic oligodendroglioma from European Organization For Research and Treatment of Cancer Trial 26951: Assessment of consensus in diagnosis, influence of 1p/19q loss, and correlations with outcome. *J Neuropathol Exp Neurol* 2007;66:545–551.
 - 20 Weller M, Berger H, Hartmann C et al. Combined 1p/19q loss in oligodendroglial tumors: Predictive or prognostic biomarker? *Clin Cancer Res* 2007;13:6933–6937.
 - 21 Jenkins RB, Blair H, Ballman KV et al. A t(1;19)(q10;p10) mediates the combined deletions of 1p and 19q and predicts a better prognosis of patients with oligodendroglioma. *Cancer Res* 2006;66:9852–9861.
 - 22 Griffin CA, Burger P, Morsberger L et al. Identification of der(1;19)(q10;p10) in five oligodendrogliomas suggests mechanism of concurrent 1p and 19q loss. *J Neuropathol Exp Neurol* 2006;65:988–994.
 - 23 Idbaih A, Marie Y, Pierron G et al. Two types of chromosome 1p losses with opposite significance in gliomas. *Ann Neurol* 2005;58:483–487.
 - 24 Kros JM, van der Weiden M, Zheng PP et al. Intratumoral distribution of 1p loss in oligodendroglial tumors. *J Neuropathol Exp Neurol* 2007;66:1118–1123.
 - 25 Lavon I, Zrihan D, Zelikovitch B et al. Longitudinal assessment of genetic and epigenetic markers in oligodendrogliomas. *Clin Cancer Res* 2007;13:1429–1437.
 - 26 Kanner AA, Staugaitis SM, Castilla EA et al. The impact of genotype on outcome in oligodendroglioma: Validation of the loss of chromosome arm 1p as an important factor in clinical decision making. *J Neurosurg* 2006;104:542–550.
 - 27 McDonald JM, See SJ, Tremont IW et al. The prognostic impact of histology and 1p/19q status in anaplastic oligodendroglial tumors. *Cancer* 2005;104:1468–1477.
 - 28 Sasaki H, Zlatescu MC, Betensky RA et al. Histopathological-molecular genetic correlations in referral pathologist-diagnosed low-grade “oligodendroglioma.” *J Neuropathol Exp Neurol* 2002;61:58–63.
 - 29 Maintz D, Fiedler K, Koopmann J et al. Molecular genetic evidence for subtypes of oligoastrocytomas. *J Neuropathol Exp Neurol* 1997;56:1098–1104.
 - 30 Hoang-Xuan K, Huguet S, Mokhtari K et al. Molecular heterogeneity of oligodendrogliomas suggests alternative pathways in tumor progression. *Neurology* 2002;57:1278–1281.
 - 31 Jeuken JWM, Sprenger SHE, Wesseling P et al. Identification of subgroups of high-grade oligodendroglial tumors by comparative genomic hybridization. *J Neuropathol Exp Neurol* 1999;58:606–612.
 - 32 Bigner SH, Matthews MR, Rasheed BKA et al. Molecular genetic aspects of oligodendrogliomas including analysis by comparative genomic hybridization. *Am J Pathol* 1999;155:375–386.
 - 33 Idbaih A, Marie Y, Lucchesi C et al. BAC array CGH distinguishes mutually exclusive alterations that define clinicogenetic subtypes of gliomas. *Int J Cancer* 2008;122:1778–1786.
 - 34 Idbaih A, Crinière E, Marie Y et al. Gene amplification is a poor prognostic factor in anaplastic oligodendrogliomas. *Neuro Oncol* 2008;10:540–547.
 - 35 Qu M, Olofsson T, Sigurdardottir S et al. Genetically distinct astrocytic and oligodendroglial components in oligoastrocytomas. *Acta Neuropathol* 2007;113:129–136.
 - 36 Trost D, Ehrler M, Fimmers R et al. Identification of genomic aberrations associated with shorter overall survival in patients with oligodendroglial tumors. *Int J Cancer* 2007;120:2368–2376.
 - 37 Nutt CL, Costello JF, Bambrick LL et al. O6 methylguanine-DNA methyltransferase in tumors and cells of the oligodendrocyte lineage. *Can J Neurol Sci* 1995;22:111–115.
 - 38 Watanabe T, Nakamura M, Kros JM et al. Phenotype versus genotype correlation in oligodendrogliomas and low-grade diffuse astrocytomas. *Acta Neuropathol* 2002;103:267–275.
 - 39 Dong SM, Pang JC, Poon WS et al. Concurrent hypermethylation of multiple genes is associated with grade of oligodendroglial tumors. *J Neuropathol Exp Neurol* 2001;60:808–816.
 - 40 Möllemann M, Wolter M, Felsberg J et al. Frequent promoter hypermethylation and low expression of the MGMT gene in oligodendroglial tumors. *Int J Cancer* 2005;113:379–385.
 - 41 Brandes AA, Tosoni A, Cavallo G et al. Correlations between O6-methylguanine DNA methyltransferase promoter methylation status, 1p and 19q deletions, and response to temozolomide in anaplastic and recurrent oligodendroglioma: A prospective GICNO study. *J Clin Oncol* 2006;24:4746–4753.
 - 42 Nutt CL, Mani DR, Betensky RA et al. Gene expression-based classification of malignant gliomas correlates better with survival than histological classification. *Cancer Res* 2003;63:1602–1607.
 - 43 Ducray F, Idbaih A, de Reyniès A et al. Anaplastic oligodendrogliomas with 1p/19q codeletion have a proneural gene expression profile. *Mol Cancer* 2008;7:41.
 - 44 Riemenschneider MJ, Reifenberger J, Reifenberger G. Frequent biallelic inactivation and transcriptional silencing of the DIRAS3 gene at 1p31 in oligodendroglial tumors with 1p loss. *Int J Cancer* 2008;122:2503–2510.
 - 45 Tews B, Roerig P, Hartmann C et al. Hypermethylation and transcriptional

- downregulation of the *CITED4* gene at 1p34.2 in oligodendroglial tumours with allelic losses on 1p and 19q. *Oncogene* 2007;26:5010–5016.
- 46 Kunitz A, Wolter M, van den Boom J et al. DNA hypermethylation and aberrant expression of the *EMP3* gene at 19q13.3 in human gliomas. *Brain Pathol* 2007;17:363–370.
 - 47 Cairncross JG, Berkey B, Shaw E et al. Phase III trial of chemotherapy plus radiotherapy compared with radiotherapy alone for pure and mixed anaplastic oligodendroglioma: Intergroup Radiation Therapy Oncology Group Trial 9402. *J Clin Oncol* 2006;24:2707–2714.
 - 48 van den Bent MJ, Carpentier AF, Brandes AA et al. Adjuvant procarbazine, lomustine, and vincristine improves progression-free survival but not overall survival in newly diagnosed anaplastic oligodendrogliomas and oligoastrocytomas: A randomized European Organisation for Research and Treatment of Cancer phase III trial. *J Clin Oncol* 2006;24:2715–2722.
 - 49 Ricard D, Kaloshi G, Amiel-Benouaich A et al. Dynamic history of low-grade gliomas before and after temozolomide treatment. *Ann Neurol* 2007;61:484–490.
 - 50 Stege EM, Kros JM, de Bruin HG et al. Successful treatment of low-grade oligodendroglial tumors with a chemotherapy regimen of procarbazine, lomustine, and vincristine. *Cancer* 2005;103:802–809.
 - 51 Hoang-Xuan K, Capelle L, Kujas M et al. Temozolomide as initial treatment for adults with low-grade oligodendrogliomas or oligoastrocytomas and correlation with chromosome 1p deletions. *J Clin Oncol* 2004;22:3133–3138.
 - 52 Buckner JC, Gesme D Jr, O'Fallon JR et al. Phase II trial of procarbazine, lomustine, and vincristine as initial therapy for patients with low-grade oligodendroglioma or oligoastrocytoma: Efficacy and associations with chromosomal abnormalities. *J Clin Oncol* 2003;21:251–255.
 - 53 Wick W, Weller M. NOA-04 randomized phase III study of sequential radiochemotherapy of anaplastic glioma with PCV or temozolomide. *Proc Am Soc Clin Oncol* 2008;26:1008s.
 - 54 Stupp R, Mason WP, van den Bent MJ et al. Radiotherapy plus concomitant and adjuvant temozolomide for glioblastoma. *N Engl J Med* 2005;352:987–996.
 - 55 Hegi ME, Diserens AC, Gorlia T et al. MGMT gene silencing and benefit from temozolomide in glioblastoma. *N Engl J Med* 2005;352:997–1003.
 - 56 Peereboom D, Brewer C, Schiff D et al. Dose-intense temozolomide in patients with newly diagnosed pure and mixed anaplastic oligodendroglioma: A phase II multicenter study. *Neuro Oncol* 2006;8:448.
 - 57 Talianky-Aronov A, Bokstein F, Lavon I et al. Temozolomide treatment for newly diagnosed anaplastic oligodendrogliomas: A clinical efficacy trial. *J Neurooncol* 2006;79:153–157.
 - 58 Vogelbaum MA, Berkey B, Peereboom D et al. Phase II trial of pre-irradiation and concurrent temozolomide in patients with newly diagnosed anaplastic oligodendrogliomas and mixed anaplastic oligoastrocytomas: RTOG BR0131. *Neuro Oncol* 2008 Sep 8 [Epub ahead of print].
 - 59 Abrey LE, Childs BH, Paleologos N et al. High-dose chemotherapy with stem cell rescue as initial therapy for anaplastic oligodendroglioma: Long-term follow-up. *Neuro Oncol* 2006;8:183–188.
 - 60 Triebels VH, Taphoorn MJB, Brandes AA et al. Salvage PCV chemotherapy for temozolomide-resistant oligodendrogliomas. *Neurology* 2004;63:904–906.
 - 61 van den Bent MJ, Chinot O, Boogerd W et al. Second-line chemotherapy with Temozolomide in recurrent oligodendroglioma after PCV (procarbazine, lomustine and vincristine) chemotherapy: EORTC Brain Tumor Group phase II study 26972. *Ann Oncol* 2003;14:599–602.
 - 62 Cairncross G, Swinnen L, Bayer R et al. Myeloablative chemotherapy for recurrent aggressive oligodendroglioma. *Neuro Oncol* 2000;2:114–119.
 - 63 Soffiotti R, Nobile M, Rudà R et al. Second-line treatment with carboplatin for recurrent or progressive oligodendroglial tumors after PCV (procarbazine, lomustine, and vincristine) chemotherapy: A phase II study. *Cancer* 2004;100:807–813.
 - 64 Chamberlain MC, Glantz MJ. CPT-11 for recurrent temozolomide-refractory 1p19q co-deleted anaplastic oligodendroglioma. *J Neurooncol* 2008;89:231–238.
 - 65 Raymond E, Brandes AA, Dittich C et al. Phase II study of imatinib in patients with recurrent gliomas of various histologies: A European Organisation for Research and Treatment of Cancer Brain Tumor Group Study. *J Clin Oncol* 2008;26:4659–4665.

Oligodendrogliomas: Molecular Biology and Treatment
Jacolien E. C. Bromberg and Martin J. van den Bent
Oncologist 2009;14;155-163; originally published online Jan 31, 2009;
DOI: 10.1634/theoncologist.2008-0248

This information is current as of March 8, 2009

**Updated Information
& Services**

including high-resolution figures, can be found at:
<http://www.TheOncologist.com/cgi/content/full/14/2/155>

 **AlphaMed Press**